

Equine Dental Care

Frequently Asked Questions & What to Look for in a Good Equine Veterinary Dentist



James M. Casey, D.V.M., M.S.
Veterinary Practitioner and Surgeon Equine
Sports Medicine, Surgery, and Dentistry
MARYLAND, VIRGINIA, PENNSYLVANIA, DELAWARE,
FLORIDA, GEORGIA, NEW JERSEY, KENTUCKY





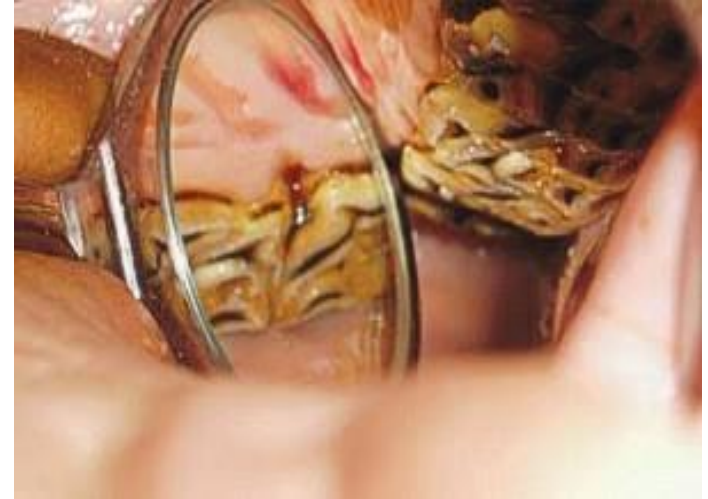**Your Horse Needs A
Dental Exam Every Year**

Why is it important for my horse to have regular dental examinations?

An oral examination should be an essential part of an annual physical examination by a veterinarian.

Every exam provides the opportunity to perform routine preventative dental maintenance.

Regular examinations also help identify dental problems while they are still in the early stage, which decreases the chances that the dental problem can lead to other serious health issues for the horse.



How often should a horse receive a dental exam?

At the minimum, all horses should receive a yearly dental exam.

Horses aged 2 to 5 years may require more frequent dental exams than older horses, as there is an extraordinary amount of dental maturation during this period.

Senior horses (20 years old or older) are at increased risk for developing periodontal disease and face the additional challenges of advancing age.

Twice-a-year examinations are often required to keep their teeth functioning properly into their third and fourth decades of life.



How will I know if my horse has a dental problem?

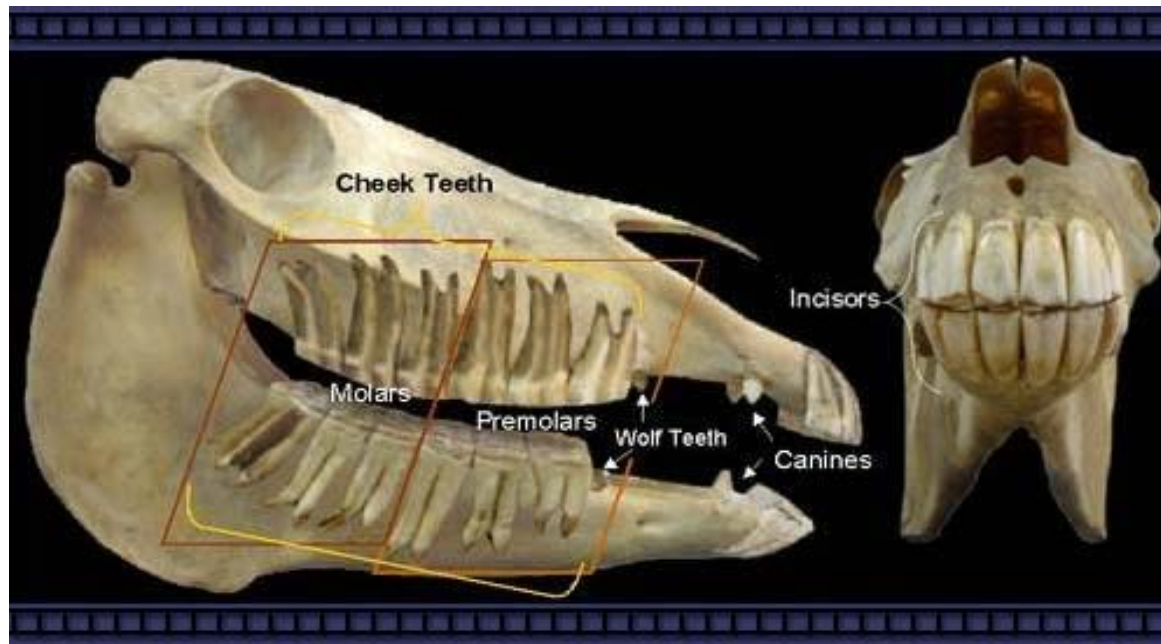


Horses with dental problems may show obvious signs such as pain or irritation, or they may show no noticeable signs at all.

Equine veterinarians skilled in dentistry are constantly amazed at how much discomfort horses will endure without any overt signals to their owners.

By the time the average owner notices a problem, such as loss of feed from the mouth while eating, fighting the bit or foul odor from the mouth or nostrils, the abnormalities inside the mouth are likely to be severe.

How many teeth does a horse have?



A typical adult male horse has 40 permanent teeth, while a typical mare may have 36 to 40 teeth, because mares are less likely to have canine (bridle) teeth.

A horse's permanent teeth are about four inches long.

Do horses have “baby” teeth?

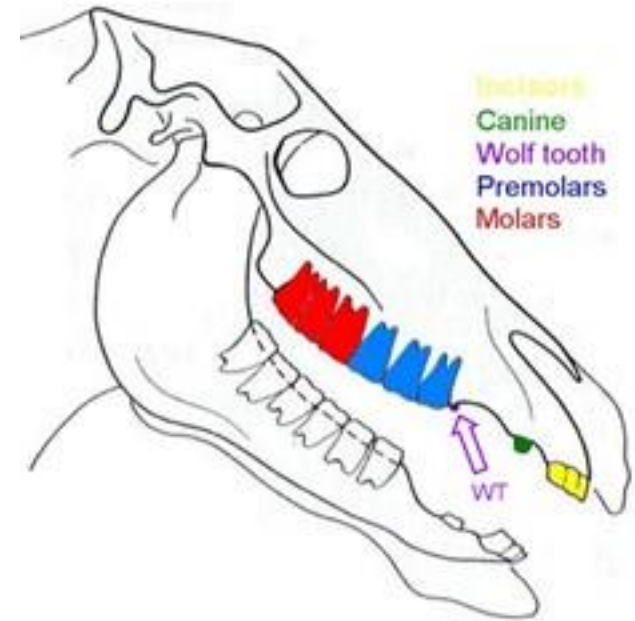
Like humans, horses have two sets of teeth in their lifetimes.

The baby teeth, called deciduous teeth, are temporary.

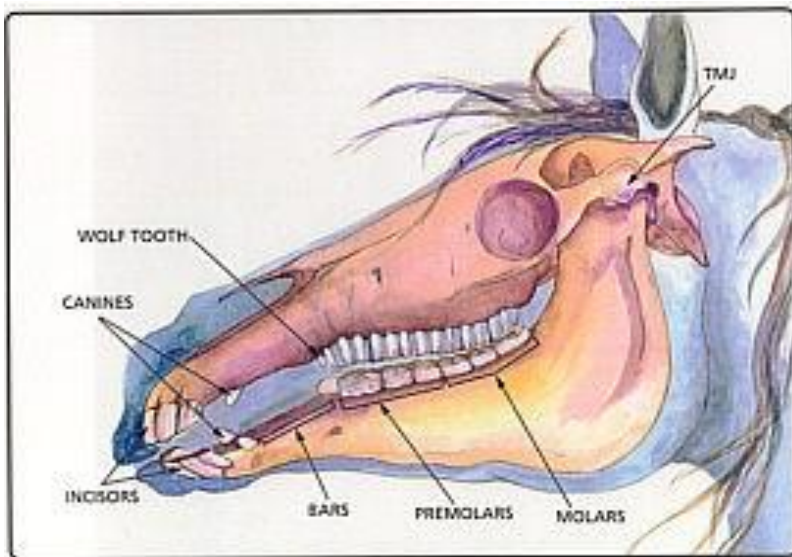
The first deciduous incisors may erupt before the foal is born.

The last deciduous teeth come in when the horse is about eight months of age.

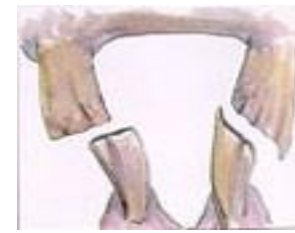These “baby” teeth will begin to be replaced by adult teeth around the age of 2 ½, and by age 5, most horses have all of their permanent teeth.



What does it mean to “float” a horse’s teeth?

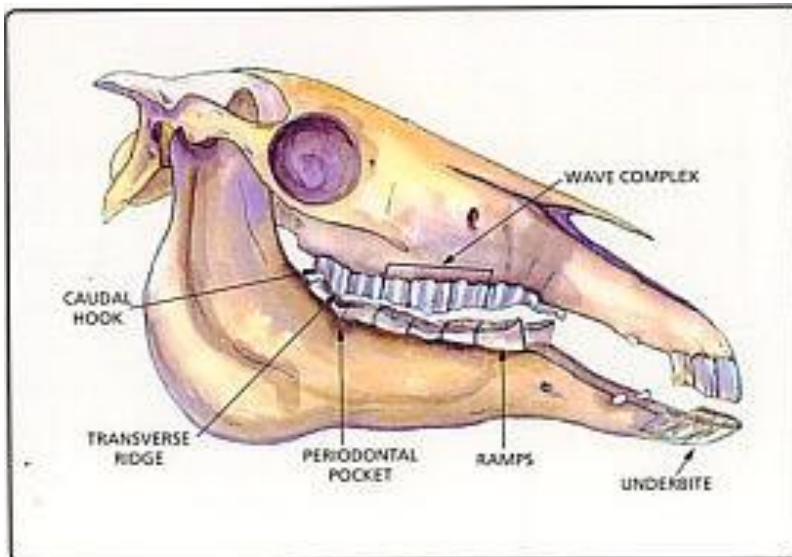


Routine maintenance horse's mouth historically as "floating."



of a has been referred to

Floating removes the sharp enamel points.



Occlusal equilibration is the term now used to describe smoothing enamel points, correcting malocclusion (faulty meeting of the upper and lower teeth), balancing the dental arcades and correcting other dental problems.

What is the difference between traditional floating and power floating?

Traditionally, horses have had their sharp enamel points and dental crown elongations reduced with hand-held rasps (floats).

These manual dental instruments have improved in quality over the past 20 years but still require a reasonable amount of manual dexterity, physical strength and "elbow grease."

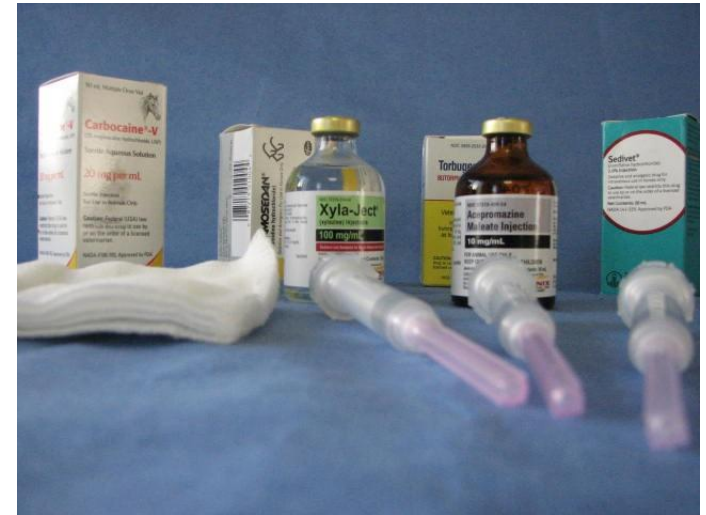High quality dental tools powered by electricity or compressed air have become readily available and affordable over the past 10 years. These instruments reduce the physical effort that is required, and with *expertise and caution*, allow for more complete and efficient dental care.



Will my horse need to be sedated during a dental exam?

Some horses find the process of having their mouth opened and instruments placed in the oral cavity to be stressful.

For a complete oral examination and good quality corrective care, most horses benefit from a mild sedative to relieve any stress or unnecessary movement on the patient's part.



Why is it important for an equine veterinarian to perform dental work on my horse?

Only a veterinarian has the medical knowledge to understand and treat a dental condition that may affect the horse's overall health.

Most equine dental procedures, including basic floating, irreversibly change the horse's teeth and therefore are most appropriately performed by a veterinarian.

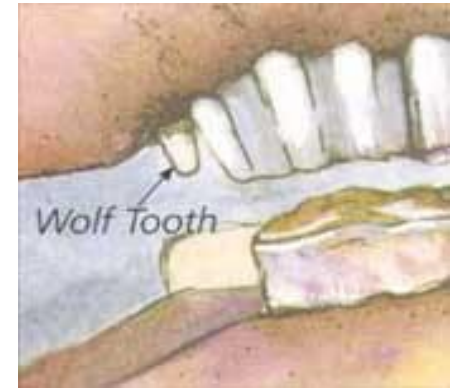The AAEP believes equine dentistry is an important branch of veterinary medicine which should only be performed by a licensed veterinarian.



What are wolf teeth?

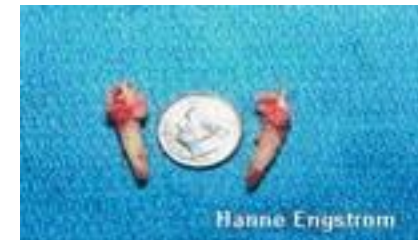Wolf teeth are the remnants of the first premolars that have now become obsolete with the evolution of the horse.

The most common first premolars seen in the horse are the uppers and they are shaped similar to small canine teeth.



This is why they are often described as wolf teeth. These sharp teeth, if present, are in the area of the mouth where the bit fits.

Wolf teeth may cause the horse some discomfort when pressure is placed on the bit. Therefore, these teeth are usually removed in young riding horses.

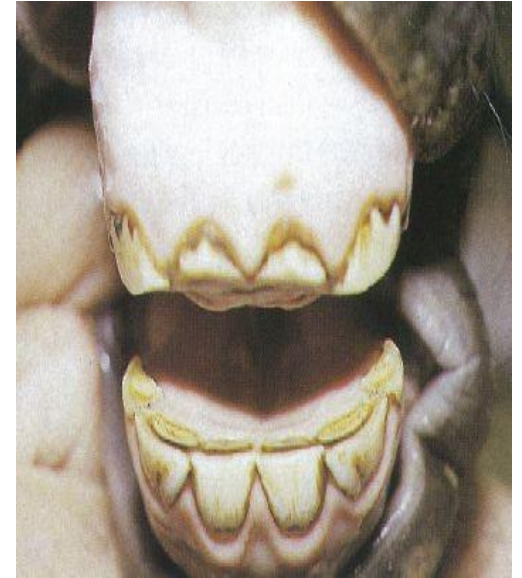


What is cribbing and how does it affect dental care?

Cribbing is a stereotypic behavior, or vice, that some horses develop.

The horse exhibits cribbing by grabbing onto an inanimate object (fence posts, buckets, stall walls, etc.) with its incisor teeth, pulling the object and often making a sucking sound.

Because these horses spend the majority of their time during the day preoccupied with this behavior rather than grazing or eating, they quite often have dental wear problems.



The upper incisor teeth (front teeth) are often worn excessively from hours of abnormal attrition. These horses are referred to as "stump suckers."

How do diet, pasture management and stabling impact dental wear?

Mother Nature designed horses to be pasture grazing animals.

Horses in the wild normally spend 16 hours a day with their heads down, grazing grass.



For a horse to properly process 20-30 pounds of wet-grass forage a day, it uses a wide, crushing chewing pattern.

This allows the incisor teeth and cheek teeth to wear at a normal and even rate.

Under artificial conditions, horses are fed an abnormal diet (grain and hay) for shorter intervals during the day, with an abnormal head posture (feed tub or hay rack).

All of these conditions alter the chewing pattern and adversely affect the way teeth are worn over time.

Do donkeys and mules require different dental care than do horses?

All equine species have the same type dentition.

We see the same types of pathology and wear patterns in donkeys, mules, zebras and horses.

Under current domestication practices, all require regular dental care.

Advances in Equine Medicine and



Veterinary Dentistry: Who Should Provide my Horse's Dental Care?



Some things you need to look for in a good equine veterinary dentist are:

Are they looking at what they are doing



They should be using portable surgical grade light (not a flash light), a padded stand, a full mouth speculum, and a veterinary assistant to steady the horse's head.

All equine dental procedures are best performed when you can see what you are doing. This work does not need to be done blindly.

Clean and Sanitary

All dental instruments, the speculum (device that holds the horse's mouth open), buckets, etc are all cleaned and washed with an antimicrobial disinfectant (I use Nolvasan Scrub and Solution) between each and every horse. **No exceptions!**



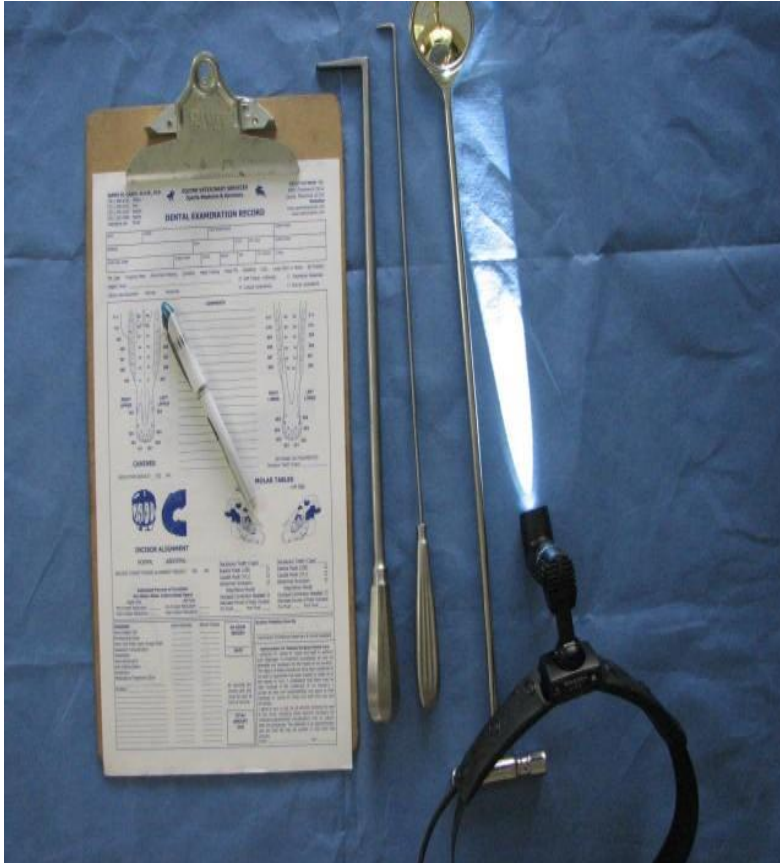Equipped to do the job



They should be well equipped with good instrumentation, both motorized and nonmotorized.

I have over 100 different instruments that I use and probably could use more.

Examination noting pathology and record keeping



A complete examination with the use of surgical grade lighting, a dental mirror, and other appropriate instruments should be done.

A record indicating all teeth in your horse's mouth, noting location and significance of all abnormalities, what work needs to be done, and time of follow up examinations should also be

included.

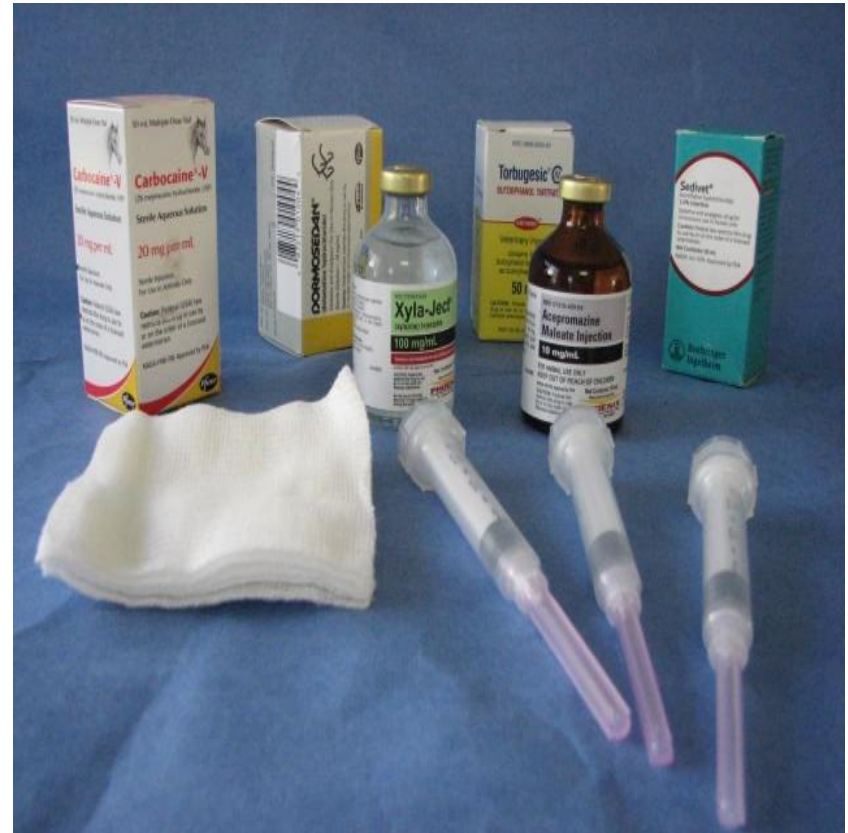Sedation and Anesthesia

This should be done when indicated and needed.

An array of medications is available to assist us when we perform dentistry.

These medications make your horse more comfortable.

When the horse is sedated, it allows us to do a better job in a safer way.



Diagnostic Imaging

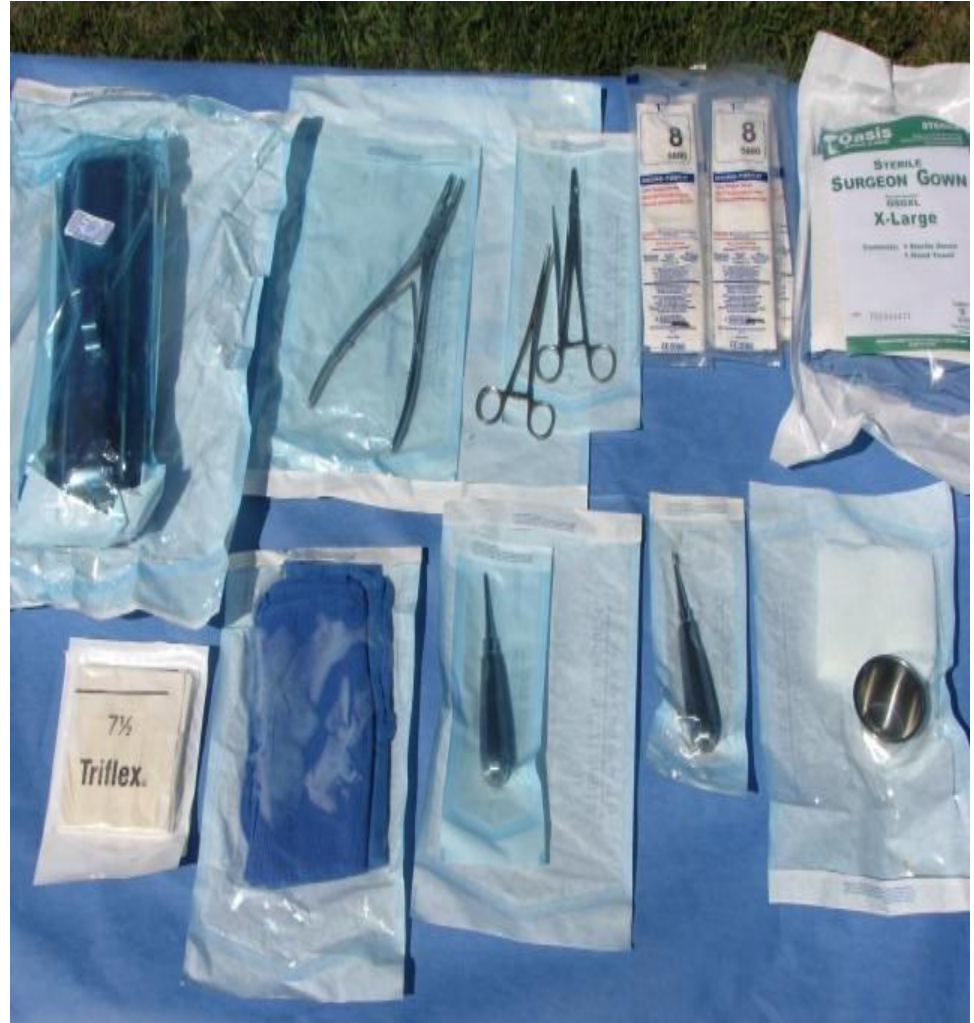

They should have access to diagnostic imaging equipment such as xrays, preferably digital xrays.

This allows us to uncover and manage a host of equine dental abnormalities.

Sterile Techniques

When any invasive procedure such as wolf teeth extraction is performed, it should be done with sterile instruments under sterile techniques.

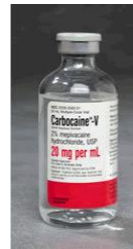
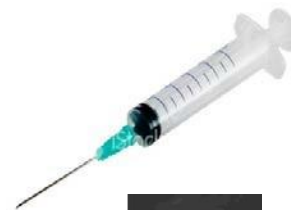
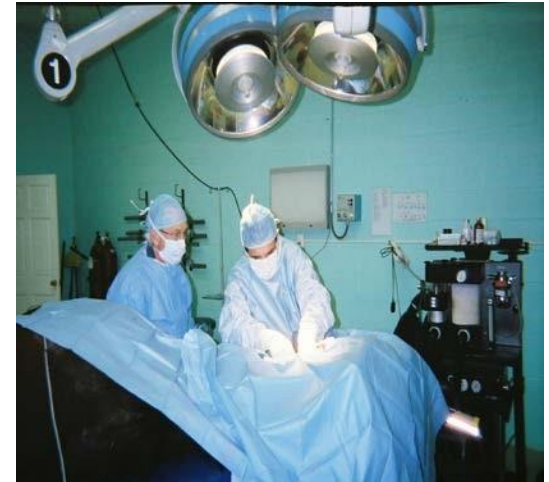I urge horse owners and trainers to regard equine dentistry as a professional service and an important part of horses' healthcare.

The services of a qualified Veterinarian also licensed to perform surgical procedures and administer medication is invaluable.

James M. Casey, D.V.M., M.S.

Part of this presentation was written by Jack Easley, D.V.M., M.S., A.B.V.P. in cooperation with the AAEP



to



James M. Casey, D.V.M., M.S.

Veterinary Practitioner and Surgeon
Equine Sports Medicine, Surgery, and Dentistry

www.equinehorsevet.com

drjamescasey@gmail.com

301-725-4371 (Office)

301-785-5167 (Cell)

Dr. Casey is a veterinarian based in Maryland practicing in the Mid-Atlantic States and Florida